

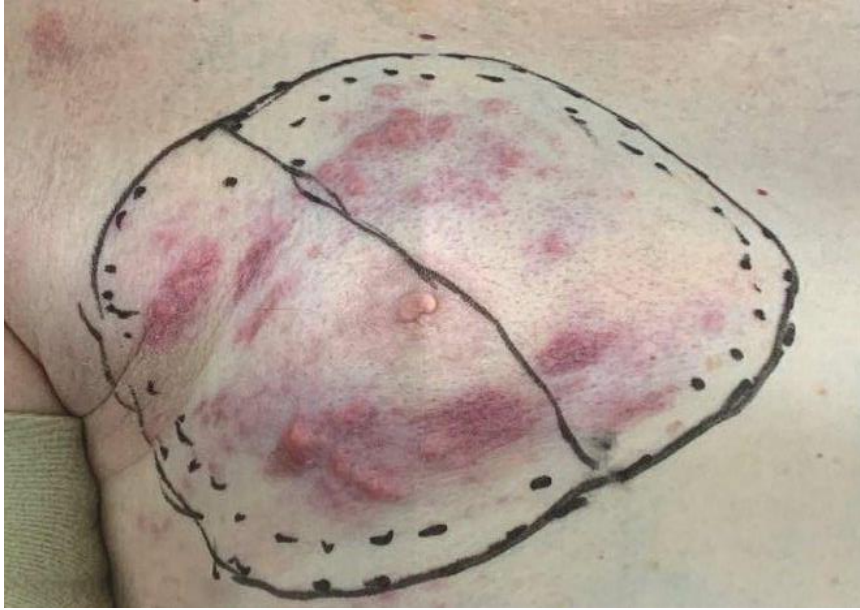

Figure 1. Multiple flesh coloured firm nodular lesions circumferential pattern on right pectoral region.

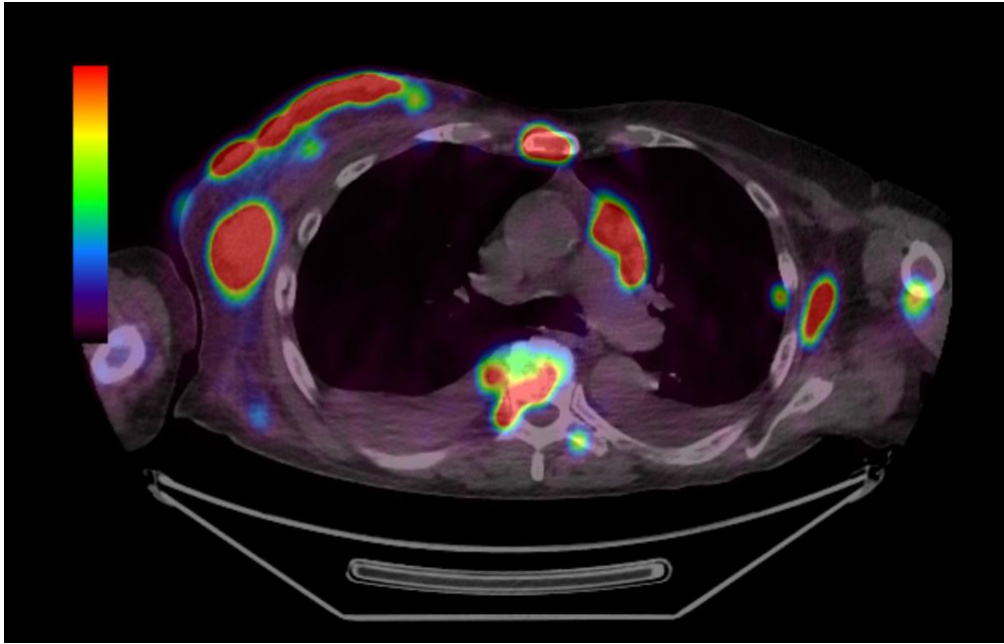


Figure 2. PSMA PET scan showing high avidity in accordance to right chest wall cutaneous lesions. (*PSMA*, prostate specific membrane antigen; *PET*, positron emission tomography)